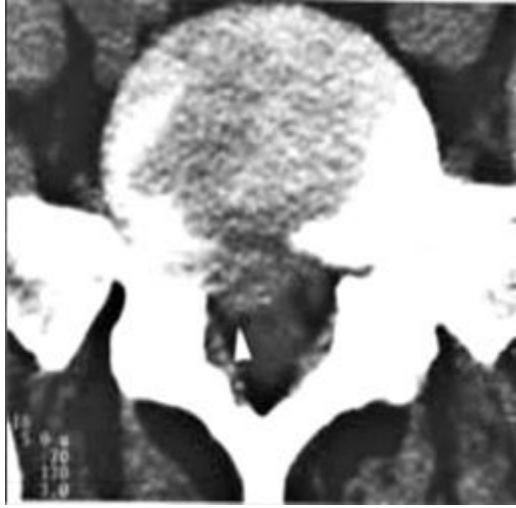
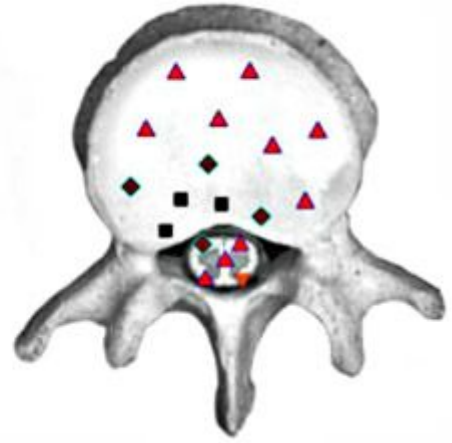


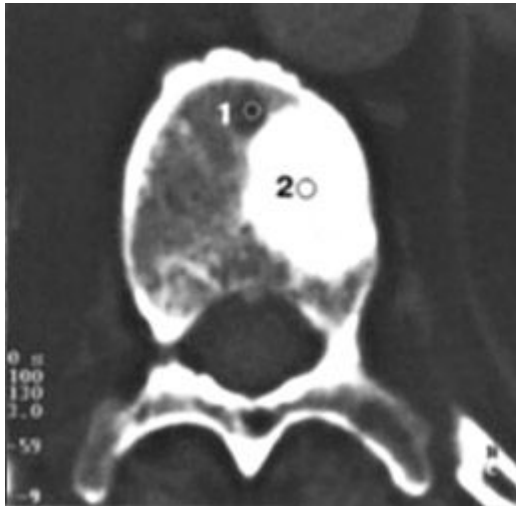
Computer Tomography



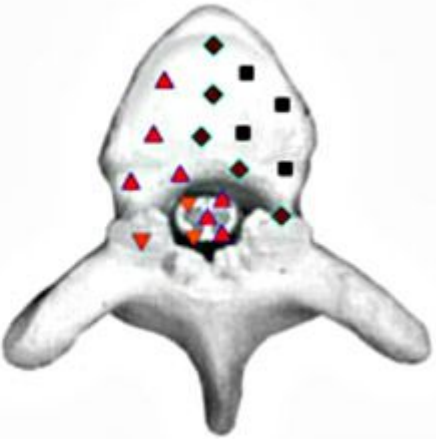
VS



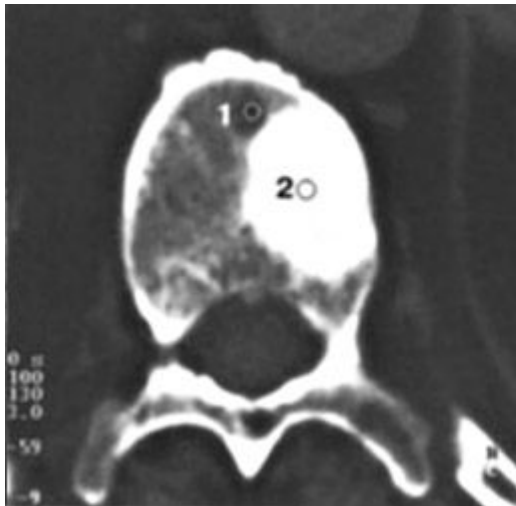
Patient S., 68 year old: Osteoplastic metastases in prostate carcinoma bone



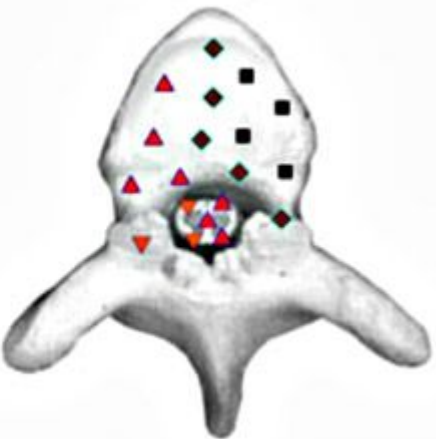
VS



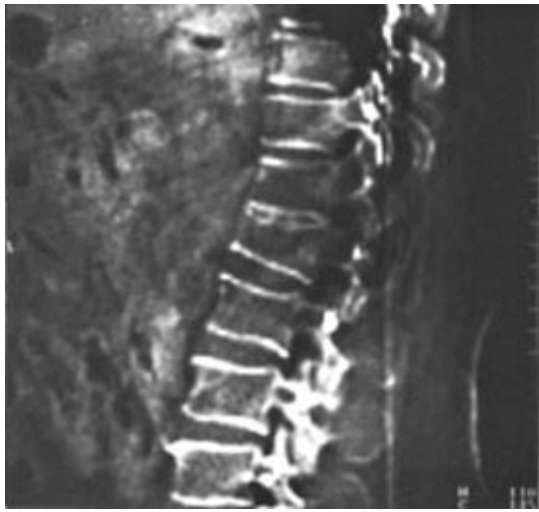Patient K., 74 years old: Metastasis of renal cell carcinoma in the lumbar vertebrae



VS



Patient N., 24 years old: Body compression fracture of the first lumbar vertebra



VS

